

# Treatment of Anterior Open Bite with the Invisalign System

WERNER SCHUPP, DMD  
JULIA HAUBRICH, DMD  
IRIS NEUMANN, DMD

Invisalign\* was initially developed to correct mild-to-moderate crowding, to close naturally occurring spaces, and to produce dental tipping.<sup>1,2</sup> After years of experience with the system, orthodontists have reported its successful use in more complex cases, such as those involving extractions, open bites, and Class II malocclusions.<sup>3-7</sup> This article describes two anterior open-bite patients who were successfully treated with the Invisalign system alone.<sup>2</sup>

## Case 1

A 15-year-old female presented with anterior open bite, anterior spacing, lack of lateral canine guidance, tongue dyskinesia, and sigmatism during speech (Fig. 1A). Before starting orthodontic treatment, she was advised to undergo myofunctional therapy.

Vertical rectangular attachments were bond-

\*Registered trademark of Align Technology, Inc., 881 Martin Ave., Santa Clara, CA 95050; www.aligntech.com.

ed to the upper incisors, canines, and first premolars and the lower canines and premolars (Fig. 1B). Thirty upper and 20 lower aligners were used to close the open bite, derotate the lower premolars, and close the anterior spaces. The refinement phase required another 10 maxillary aligners—seven for a 1.1mm extrusion of the maxillary incisors and three for retraction and space closure.

After 20 months of aligner treatment, the anterior open bite had been closed, the spaces between the central incisors had been closed in both arches, and canine guidance had been achieved bilaterally, with functional overjet and overbite (Fig. 2A). The final ClinCheck projections closely matched the post-treatment results (Fig. 2B); frontal superimpositions of the ClinCheck pretreatment analysis and post-treatment projection indicated the amount of relative extrusion needed for closure of the open bite (Fig. 2C).

The patient's bite closure and other corrections remained stable 12 months after the completion of Invisalign treatment (Fig. 3).



Dr. Schupp

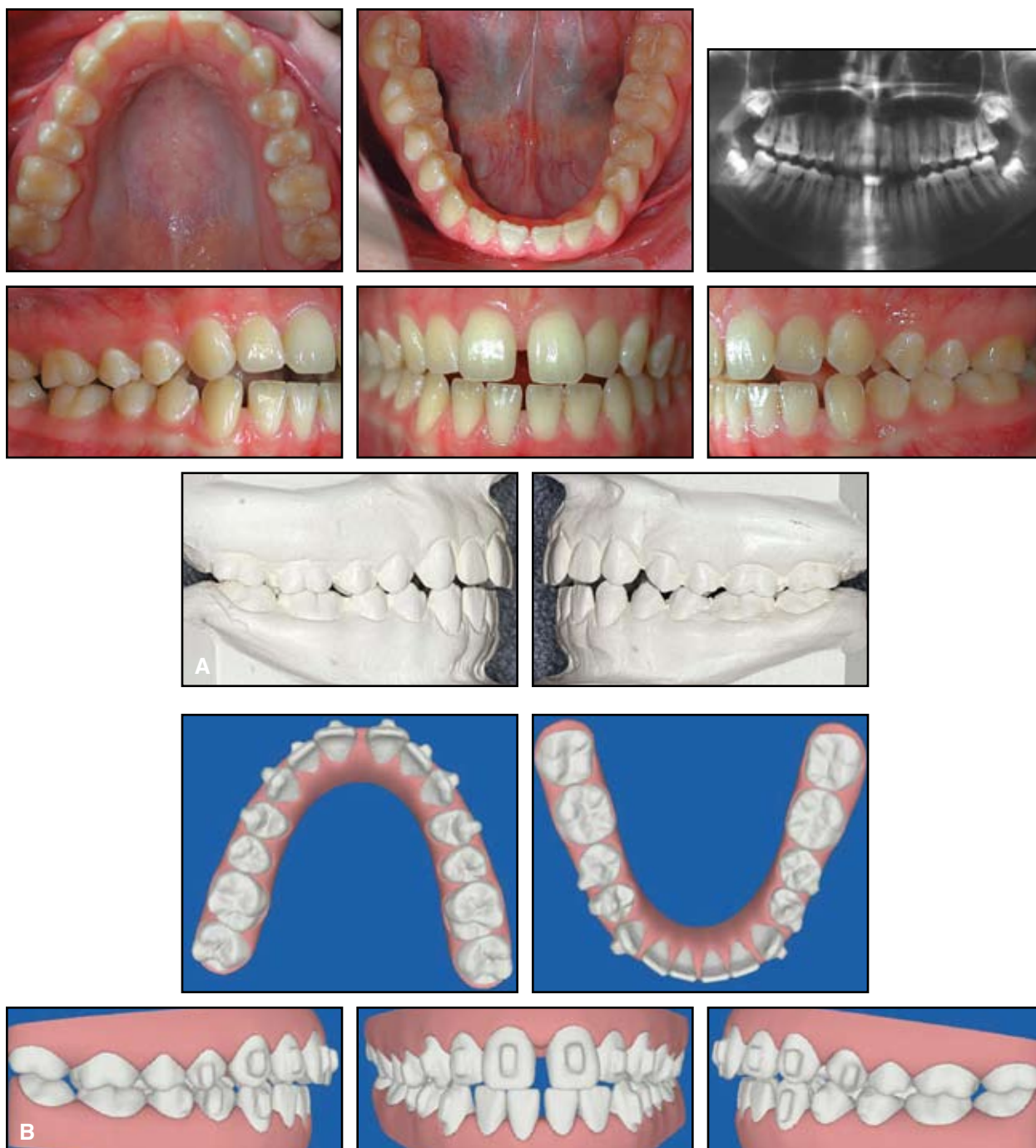


Dr. Haubrich



Dr. Neumann

The authors are in the private practice of orthodontics at Hauptstrasse 50, 50996 Köln, Germany. Dr. Schupp is a Visiting Professor, Department of Orthodontics, University of Ferrara, Italy; e-mail: praxis@schupp-ortho.de. Drs. Schupp and Haubrich are members of Align Technology's Clinical Education Council.



**Fig. 1 Case 1. A.** 15-year-old female with anterior open bite, anterior spacing, and lack of lateral canine guidance before treatment. **B.** Pretreatment ClinCheck\* analysis, showing bonded vertical attachments on upper incisors, canines, and first premolars and lower canines and premolars.

\*Registered trademark of Align Technology, Inc., 881 Martin Ave., Santa Clara, CA 95050; [www.aligntech.com](http://www.aligntech.com).

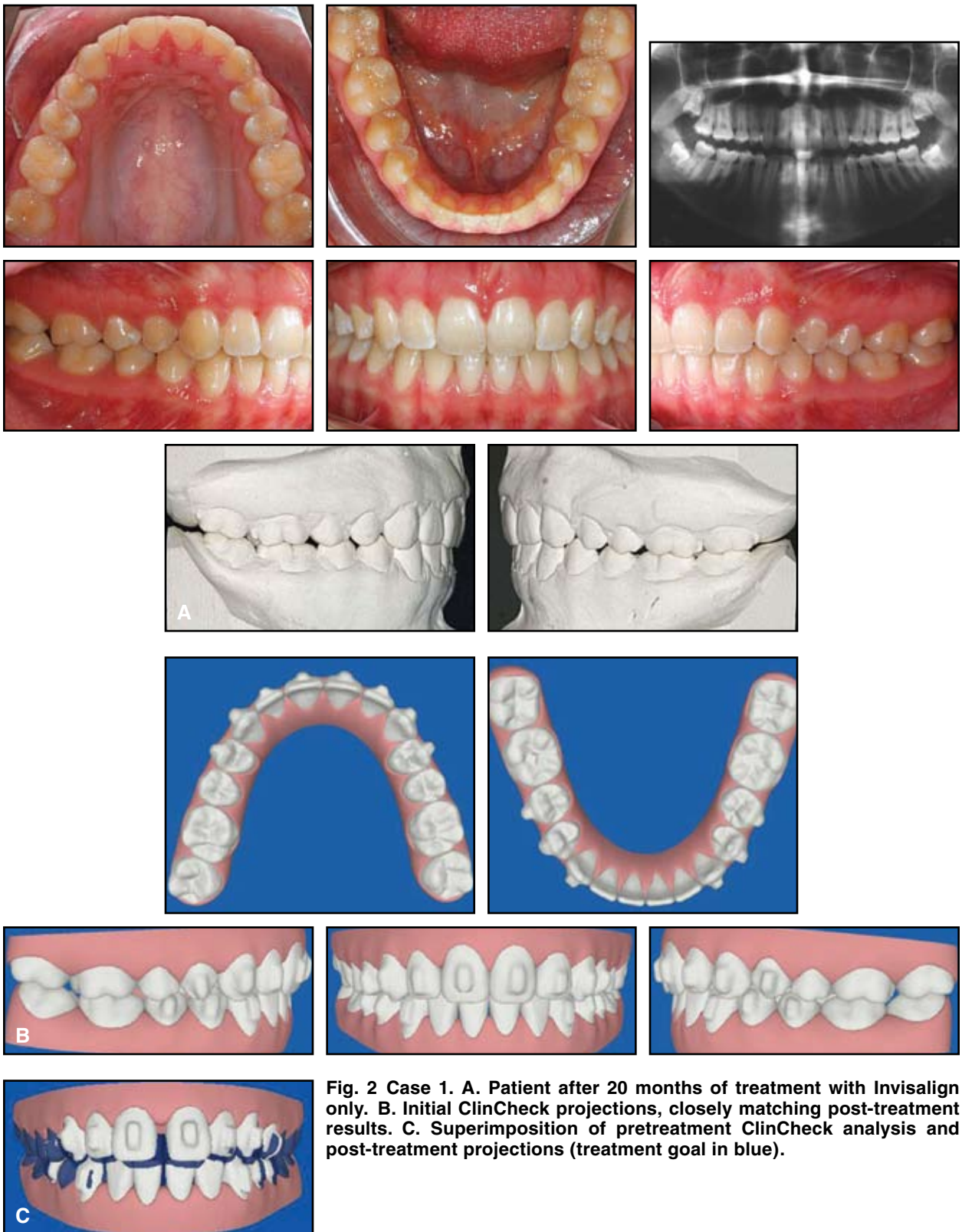
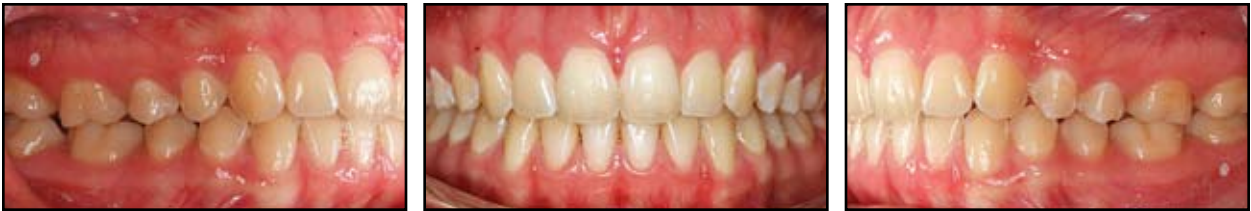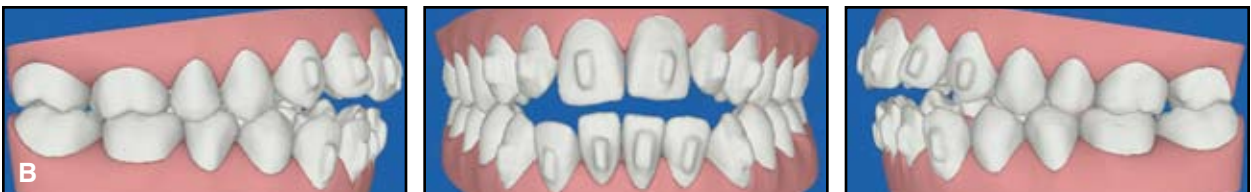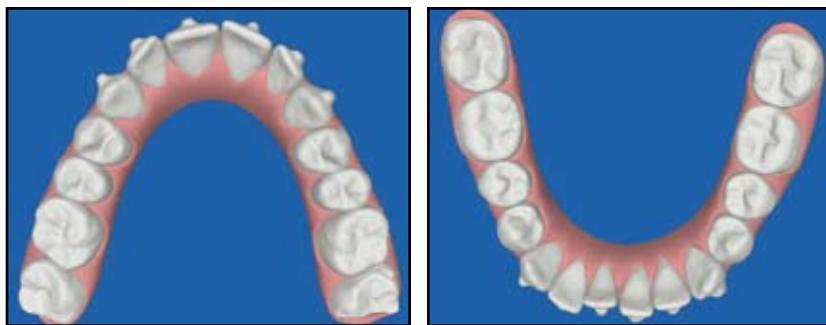
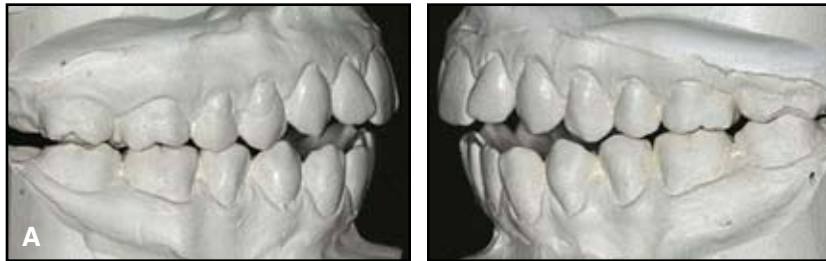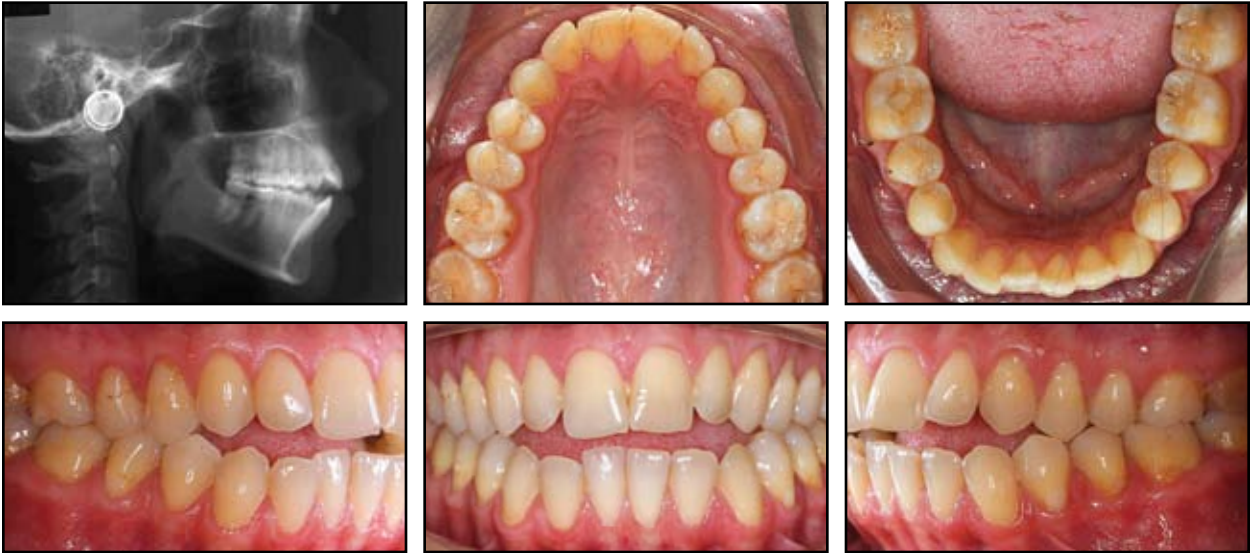


Fig. 2 Case 1. A. Patient after 20 months of treatment with Invisalign only. B. Initial ClinCheck projections, closely matching post-treatment results. C. Superimposition of pretreatment ClinCheck analysis and post-treatment projections (treatment goal in blue).



**Fig. 3 Case 1. Stability of closed anterior bite and anterior spacing 12 months after end of treatment.**

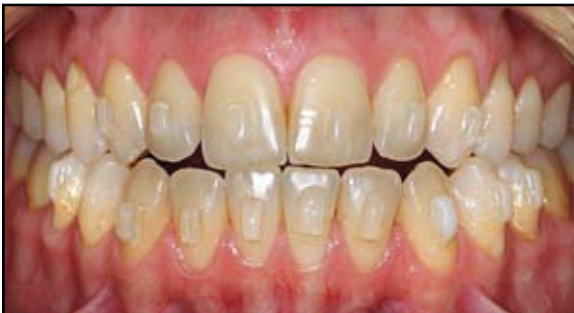

**Fig. 4 Case 2. A. 31-year-old female with Class I molar relationship, anterior open bite, and anterior crowding before treatment. B. Pretreatment ClinCheck analysis, showing bonded attachments on upper and lower incisors and canines.**

## Case 2

A 31-year-old female presented with anterior open bite, a Class I molar relationship, and anterior crowding in both arches (Fig. 4A). Ricketts analysis confirmed an open bite with no skeletal component (lower facial height =  $42.6^\circ$ ). We advised myofunctional therapy to correct the pattern of tongue-thrust swallowing and orofacial dyskinesia.

Bonded attachments were placed from canine to canine in both arches for extrusion of the anterior teeth (Fig. 4B). The first phase of Invisalign treatment involved 20 upper and 14 lower aligners.



**Fig. 5** Case 2. Progress of bite closure after nine sets of aligners.

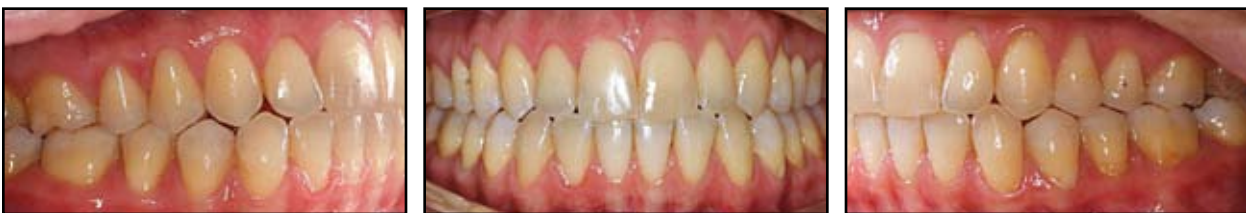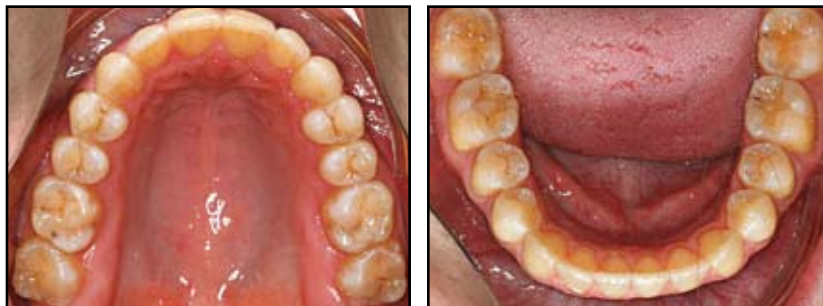After nine sets of aligners, the open bite had started to close (Fig. 5). After 10 months of treatment, with her bite almost closed, the patient requested removal of the attachments for her wedding (Fig. 6). Two weeks later, case refinement began with new attachments bonded to the lower right canine and premolars for extrusion to close the remaining lateral open bite. Nine upper and 10 lower aligners were used in the refinement phase.

After 17 months of active treatment, the anterior open bite had been completely closed, proper overbite and overjet had been established, the anterior teeth had been well aligned, and canine guidance had been achieved on both sides, closely matching the ClinCheck projections (Fig. 7). The upper incisors and canines had been extruded about 2.5mm and the lower incisors and canines 2mm; the molars had been intruded about 1mm.

The patient wore aligners for retention. Fourteen months after the end of Invisalign treatment, the results remained stable (Fig. 8).

## Discussion

Dentoalveolar open bites can be caused by speech disorders, oral habits, or mouthbreathing



**Fig. 6** Case 2. After 10 months of treatment, attachments temporarily removed for esthetic reasons.

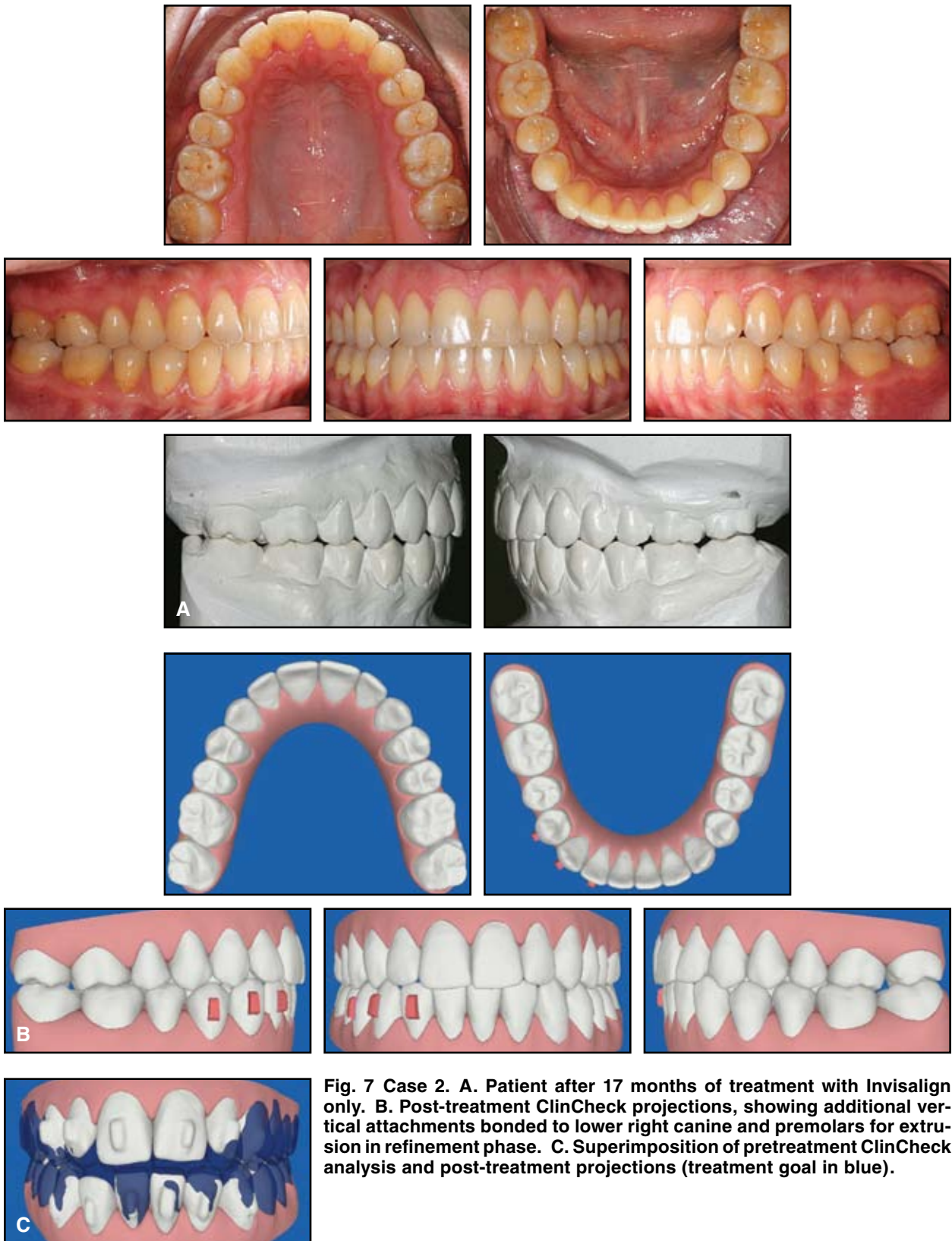
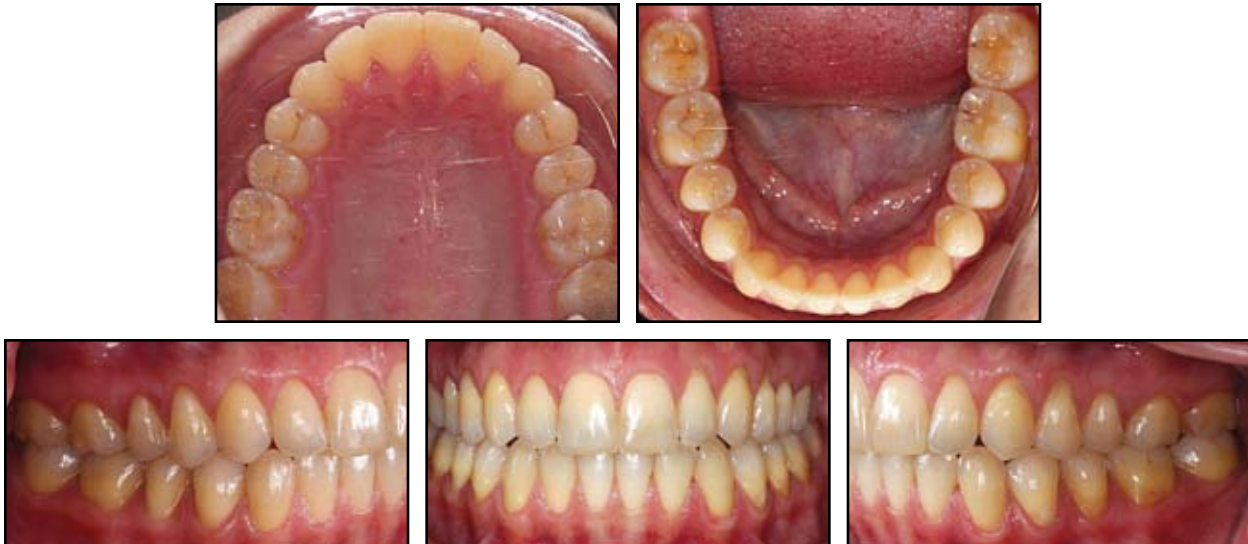

Fig. 7 Case 2. A. Patient after 17 months of treatment with Invisalign only. B. Post-treatment ClinCheck projections, showing additional vertical attachments bonded to lower right canine and premolars for extrusion in refinement phase. C. Superimposition of pretreatment ClinCheck analysis and post-treatment projections (treatment goal in blue).



**Fig. 8 Case 2. Stability of closed anterior bite 14 months after end of Invisalign treatment.**

due to enlarged lymphatic tissues.<sup>8-10</sup> Positioning of the tongue during swallowing, speech, and rest plays an important role in the development of open bites.<sup>11</sup> In such cases, consultation between the orthodontist, otorhinolaryngologist, and myofunctional therapist becomes necessary before and during orthodontic treatment. As seen in both patients presented here, it is important to obtain a functional tongue position through myofunctional therapy to ensure stability of the treatment results.

Invisalign offers a comfortable and almost invisible treatment option for closing anterior open bites. Simulated rotation of the mandible in the ClinCheck analysis can be helpful if intrusion of the posterior segments is planned. Virtual articulation of the arches in centric relation may also be desirable in patients with craniomandibular disorders.

Close monitoring during the retention phase is required to prevent reopening of the open bite. The retention protocol for an open bite treated with Invisalign appliances should be identical to that in a case treated with fixed appliances.

#### REFERENCES

1. Vlaskalic, V. and Boyd, R.: Orthodontic treatment of a mildly crowded malocclusion using the Invisalign System, *Austral. Orthod. J.* 17:41-46, 2001.
2. Boyd, R.L.: Esthetic orthodontic treatment using the invisalign appliance for moderate to complex malocclusions, *J. Dent. Ed.* 72:948-967, 2008.
3. Boyd, R.L.: Complex orthodontic treatment using a new protocol for the Invisalign appliance, *J. Clin. Orthod.* 41:525-547, 2007.
4. Honn, M. and Goz, G.: A premolar extraction case using the Invisalign system, *J. Orofac. Orthop.* 67:385-394, 2006.
5. Womack, W.R.: Four-premolar extraction treatment with Invisalign, *J. Clin. Orthod.* 40:493-500, 2006.
6. Womack, W.R. and Day, R.H.: Surgical-orthodontic treatment using the Invisalign system, *J. Clin. Orthod.* 42:237-245, 2008.
7. Norris, R.A.; Brandt, D.J.; Crawford, C.H.; and Fallah, M.: Restorative and Invisalign: A new approach, *J. Esth. Restor. Dent.* 14:217-224, 2002.
8. Fujiki, T.; Inoue, M.; Miyawaki, S.; Nagasaki, T.; Tanimoto, K.; and Takano-Yamamoto, T.: Relationship between maxillo-facial morphology and deglutitive tongue movement in patients with anterior open bite, *Am. J. Orthod.* 125:160-167, 2004.
9. Larsson, E.: The effect of dummy-sucking on the occlusion: A review, *Eur. J. Orthod.* 8:127-130, 1986.
10. Larsson, E.: The effect of finger-sucking on the occlusion: A review, *Eur. J. Orthod.* 9:279-282, 1987.
11. Subtelny, J.D.: Oral habits—studies in form, function, and therapy, *Angle Orthod.* 43:349-383, 1973.